



HAL
open science

Did Cro-Magnon 1 have neurofibromatosis type 1?

Philippe Charlier, Nadia Benmoussa, Philippe Froesch, Isabelle
Huynh-Charlier, Antoine Balzeau

► **To cite this version:**

Philippe Charlier, Nadia Benmoussa, Philippe Froesch, Isabelle Huynh-Charlier, Antoine Balzeau.
Did Cro-Magnon 1 have neurofibromatosis type 1?. *The Lancet*, 2018, 391 (10127), pp.1259.
10.1016/S0140-6736(18)30495-1 . insu-04016768

HAL Id: insu-04016768

<https://insu.hal.science/insu-04016768>

Submitted on 6 Mar 2023

HAL is a multi-disciplinary open access archive for the deposit and dissemination of scientific research documents, whether they are published or not. The documents may come from teaching and research institutions in France or abroad, or from public or private research centers.

L'archive ouverte pluridisciplinaire **HAL**, est destinée au dépôt et à la diffusion de documents scientifiques de niveau recherche, publiés ou non, émanant des établissements d'enseignement et de recherche français ou étrangers, des laboratoires publics ou privés.

4 Young S, for The Independent. Liver disease to become biggest killer by 2020 with alcohol and obesity to blame. Dec 1, 2017. <http://www.independent.co.uk/life-style/liver-disease-premature-death-cause-killer-alcohol-obesity-a8086441.html> (accessed Jan 26, 2018).

Did Cro-Magnon 1 have neurofibromatosis type 1?

The Cro-Magnon 1 skeleton corresponds to a 28 000 BCE *Homo sapiens* male individual that was discovered in 1868 in a rock shelter in Les Eyzies, France.¹ Since its discovery, various diagnoses have been proposed with regards to a round polycyclic osteolytic lesion on the right frontal bone, measuring 37 mm x 27 mm (appendix): post-mortem alteration due to the soil,² rickets,³ actinomycosis,⁴ and Langerhans cell histiocytosis.⁵

Recently, we did a medical CT scan, followed by a micro CT scan, on the lesion. The results showed the exact bone aspect of the pathological zone and peripheral limits (figure A): a limited resorption of the external cortical bone, of granular aspect, without peripheral sclerosis in the internal table, which excludes a malignant transformation. This aspect agrees with the radiological morphology of a subcutaneous schwannoma with progressive bone erosion in the context of neurofibromatosis type 1, as confirmed by biomedical literature^{6,7} and direct comparison with palaeopathological reference collections (for example, skull 101 of the Tessier collection, in Amiens, France).

Additionally, an asymmetry of the size of the internal auditory meatus is visible after a micro CT scan examination and three-dimensional reconstruction of the Cro-Magnon 1 skull (appendix), which could be related to the development of an acoustic neurinoma (a schwannoma).⁸ Examination of other nerve foramina at the level of the skull base did not

show any anomaly. Although acoustic neurinomas are more frequent in neurofibromatosis type 2, they have also been reported in type 1.⁹ Cases of internal auditory meatus enlargement in neurofibromatosis type 1 have also been described without any associated acoustic nerve tumour, with the cause of the enlargement being related to bone dystrophy (bony dysplasia) or dural ectasia.¹⁰

According to this retrospective diagnosis, a new facial reconstruction of this individual can be proposed, featuring the macroscopic aspect of the disease (figure B). A further analysis of the rest of the skeleton might be of interest to search for other bone lesions with characteristics of low growth rate.

We declare no competing interests.

*Philippe Charlier, Nadia Benmoussa, Philippe Froesch, Isabelle Huynh-Charlier, Antoine Balzeau
philippe.charlier@uvsq.fr

Section of Medical Anthropology, University of Versailles Saint-Quentin-en-Yvelines, 78180 Montigny-Le-Bretonneux, France (PC, NB, PF, IH-C); Centre d'Accueil et de Soins Hospitaliers and Institut de la Précarité et de l'Exclusion Sociale, Nanterre, France (PC); Department of Otolaryngology—Head and Neck Surgery, Rouen University Hospital, Rouen, France (NB); Department of Radiology, University Hospital Pitié-Salpêtrière, Paris, France (IH-C); and Section of Human Paleontology, Department of Prehistory, National Museum of Natural History, Musée de l'Homme, Paris, France (AB)

- 1 Balzeau A, Grimaud-Hervé D, Déroît F, Holloway RL, Combès B, Prima S. First description of the Cro-Magnon 1 endocranium and study of brain variation and evolution in anatomically modern *Homo sapiens*. *Bull Mem Soc Anthropol Paris* 2013; **25**: 1–18.
- 2 Broca P. Sur les crânes et ossements des Eyzies. *Bull Soc Anthropol Paris* 1868; **3**: 350–92.
- 3 Collective discussion. Sur les crânes et les ossements des Eyzies. *Bull Soc Anthropol Paris* 1868; **3**: 416–46, 454–514, 554–78.
- 4 Dastugue J. Pathologie des hommes fossiles de l'abri de Cro-Magnon. *L'Anthropologie* 1967; **71**: 479–92 (in French).
- 5 Thillaud PL. L'histiocytose X au Paléolithique (sujet no 1 de Cro-Magnon): problématique du diagnostic ostéo-archéologique. *L'Anthropologie (Paris)* 1981; **85**: 219–39.
- 6 National Institutes of Health Consensus Development Conference. Neurofibromatosis: conference statement. *Arch Neurol* 1988; **45**: 575–78.

7 Kühnisch J, Set J, Lange C, et al. Multiscale, converging defects of macro-porosity, microstructure and matrix mineralization impact long bone fragility in NF1. *PLoS One* 2014; **9**: e86115.

8 Valvassori GE. The radiological diagnosis of acoustic neuromas. *Arch Otolaryngol* 1966; **83**: 582–87.

9 Hekmatnia A, Ghazavi A, Marashi Shoostari MJ, Hekmatnia F, Basiratnia R. Imaging review of neurofibromatosis: helpful aspects for early detection. *Iran J Radiol* 2011; **8**: 63–74.

10 Kitamura K, Senba T, Komatsuzaki A. Bilateral internal auditory canal enlargement without acoustic nerve tumor in von Recklinghausen neurofibromatosis. *Neurofibromatosis* 1989; **2**: 47–52.



See Online for appendix

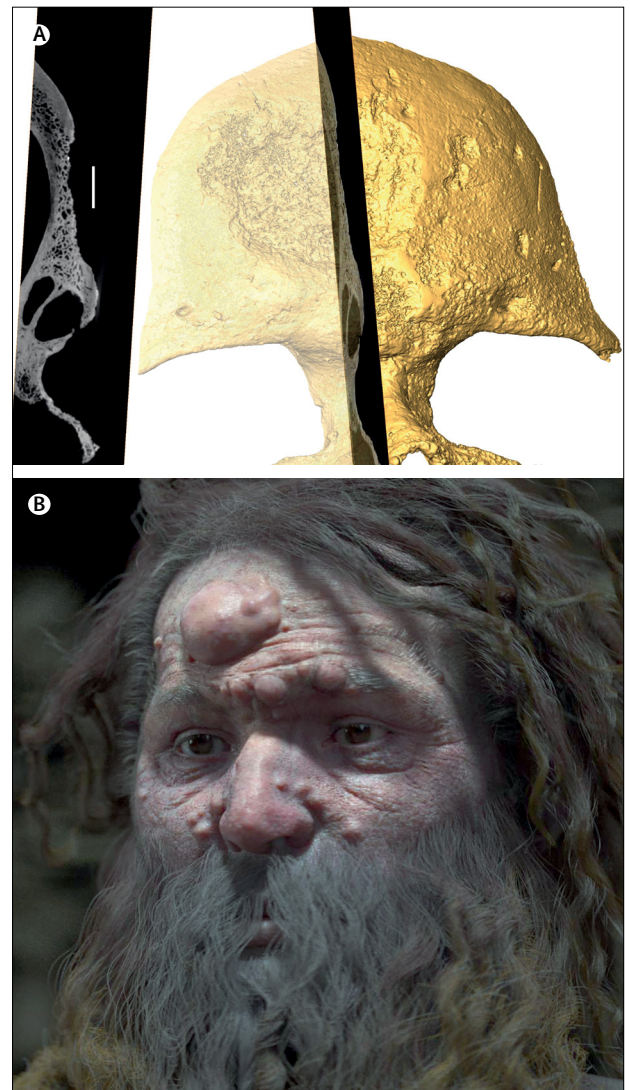


Figure: Features of the lesion in the Cro-Magnon 1 skull

(A) Detail of the bone erosion at the micro CT examination; bar is 0.5 cm. (B) Full facial reconstruction with clear visibility of the benign tumour on the frontal zone.